



















## Significance of *Croton lobatus* L. leaf extract on the healing of surgically created wounds in laboratory rats

Muhyideen A. Kilani<sup>1</sup>  , Lateefat O. Oladimeji<sup>2</sup>  , Iskiil O. Oyenekan<sup>3\*</sup>    
Abdulahakeem Binhabali<sup>7\*</sup>  , Hassan A. Audu<sup>1</sup>  , Abdulrauf M. Obalowu<sup>4</sup>    
Abdullahi Aliyu<sup>5</sup>  , Adamu Z. Hassan<sup>6</sup>  , and Samuel T. Fadason<sup>6</sup>  

<sup>1</sup> Department of Veterinary Surgery and Radiology, College of Veterinary Medicine, Federal University of Agriculture Zuru, P.M.B. 28, Kebbi State, Nigeria, <sup>2</sup> Department of Animal Science, Al-Hikmah University, Ilorin, Kwara State

<sup>3</sup> Department of Veterinary Surgery and Theriogenology, College of Veterinary Medicine, Federal University of Agriculture Abeokuta, Ogun State, Nigeria, <sup>4</sup> Veterinary Teaching Hospital, University of Ilorin, Ilorin.

<sup>5</sup> Department of Veterinary Surgery and Radiology, Faculty of Veterinary Medicine, University of Ilorin, Ilorin.

<sup>6</sup> Department of Veterinary Surgery and Radiology, Faculty of Veterinary Medicine, Ahmadu Bello University, Zaria, Kaduna State.

<sup>7</sup> Department of Clinical Sciences, College of Veterinary Medicine, Tuskegee University, Tuskegee, Alabama, USA

\* Author to whom correspondence should be addressed

**Article number:** 211, **Received:** 14-04-2025, **Accepted:** 18-06-2025, **Published online:** 25-06-2025

**Copyright**© 2025. This open-access article is distributed under the [Creative Commons Attribution License](#), which permits unrestricted use, distribution, and reproduction in any medium, provided the original work is properly cited.

### HOW TO CITE THIS

Kilani et al. (2025) Significance of *Croton lobatus* L. leaf extract on the healing of surgically created wounds in laboratory rats. *Mediterr J Pharm Pharm Sci.* 5(2): 141-151. [Article number: 211]. <https://doi.org/10.5281/zenodo.15741778>

**Keywords:** *Croton lobatus*, cicatrin powder, pain, wounds, wound healing

**Abstract:** *Croton lobatus* (*C. lobatus*), has traditionally been utilized for its purported wound-healing properties. Despite its use, scientific validation of its efficacy remains limited. This study aims to evaluate the effects of *C. lobatus* leaf extracts on wound healing by examining wound contraction, epithelialization, histopathological changes, and biochemical markers in a rat excision wound model. 22-week-old albino rats with body weight of 200 g, were anesthetized, and four excision wounds measuring 1.0 by 1.0 cm were surgically created on their dorsal surfaces. The rats were randomly assigned to four treatment groups: Group A received topical applications of *C. lobatus* paste; Group B was treated with *C. lobatus* aqueous extract; Group C served as the control group and was treated with saline solution; and Group D received Cicatrin powder, a commercial antibacterial agent (neomycin & bacitracin). Treatments commenced 48 hrs post-wound creation. Groups A to C, each comprising three rats, underwent gross examination to monitor wound contraction and epithelialization on days 4, 6, 8, 10, and 12 post-wounding. On day 22, following complete healing, biopsies were collected for tensometric analysis. In Group D, one rat was sacrificed on days 4, 7, 10, and 13 post-wounding to facilitate histopathological examination and to assess levels of hydroxyproline, hexosamine, total protein, and uronic acid in the granulation tissue. The study revealed that wounds treated with *C. lobatus* paste and aqueous extract exhibited significantly higher mean percentages of wound contraction compared to those treated with Cicatrin powder. Similarly, the mean percentages of epithelialization were markedly greater in the *C. lobatus*-treated groups relative to the Cicatrin group. Histopathological assessments indicated a moderate to abundant presence of active fibroblasts in the *C. lobatus*-treated wounds, whereas the normal saline and Cicatrin groups exhibited fewer fibroblasts. Biochemical analyses demonstrated that granulation tissues from the *C. lobatus*-treated wounds contained higher levels of hydroxyproline, hexosamine, total protein, and uronic acid, suggesting enhanced collagen synthesis and

extracellular matrix formation. This study suggests that the paste and aqueous extracts of *C. lobatus* significantly promote wound healing and improve biochemical markers associated with tissue repair.

## Introduction

Wound healing is a complex physiological process essential for restoring the skin's structure, integrity, and function [1, 2]. Chronic wounds, in particular, pose significant challenges to both patients and clinicians [3]. Traditional treatments, such as oral and topical antibiotics, often prove ineffective for non-healing wounds [4]. While stem cell therapies have been explored [5, 6], their high costs render them inaccessible to many, especially in developing countries like Nigeria. The genus *Croton* has been scientifically validated for various therapeutic effects, leading to new drug developments [7]. *Croton dichogamus* Pax, for instance, is commonly used by local populations to manage various ailments [8]. The sap of *Croton lechleri*, known as "Dragon's Blood," has demonstrated efficacy in wound healing and the treatment of gastric and duodenal ulcers [9, 10]. It promotes skin regeneration in conditions like varicose ulcers and bedsores [11]. *Croton lobatus* (*C. lobatus*), commonly known as Rusffoil or Lobed croton, is recognized in Nigeria by various names: "gaásàyaá" in Hausa, "òkwè" in Igbo, and "àjéofòlè" or "èru" in Yoruba [12, 13]. Native to the Caribbean, North America, South America, and the West Indies, it has been introduced to regions like Senegal, Eritrea, Ethiopia, the Arabian Peninsula, and Bangladesh. Traditionally, *C. lobatus* is applied topically to treat ulcers, sores, and headaches [12]. In Nigeria, a decoction made by boiling the plant is consumed to address chronic wounds [14]. Additionally, its leaves are boiled with *Bidens pilosa* and *Calopogonium mucunoides* for treating ulcers, wounds, and sores [15]. Despite its traditional use, there is a lack of scientific research validating the efficacy of *C. lobatus* in wound management. This study aims to fill that gap by investigating the mechanisms through which *C. lobatus* influences wound healing, marking the first extensive research on this plant's potential therapeutic properties.

## Materials and methods

**Collection of samples:** The leaves of the *C. lobatus* (Plate 1a & b) were collected from Obokun Local Government Area of Osun State Nigeria and were confirmed in the Herbarium of the Botanical Garden of Ahmadu Bello University, Zaria, with a voucher specimen number of 913. The leaves were air-dried under the shade at room temperature. The dried powder of the plant was extracted with sterile distilled water [16]. Leaf paste was prepared from dried *C. lobatus*. This was applied topically as it is traditionally used (A). 50 g of each extract was dissolved in 100 ml of distilled water (500 mg/ml) for use.

**Experimental design:** Thirteen 22-week-old Albino rats, each weighing approximately 190 to 200 g, were selected for this study. The animals were housed individually in steel cages, provided with commercial rat feed, and had free access to water ad libitum. A two-week acclimatization period preceded the experimental procedures. Anesthesia was induced via intramuscular injection of ketamine hydrochloride (40 mg/kg) combined with xylazine hydrochloride (5.0 mg/kg). Prior to surgery, each rat's body was decontaminated using diluted chlorhexidine gluconate. The dorsal region was shaved and sterilized to prepare for aseptic surgery. Using a sterile 1.0 by 1.0 cm stencil, four full-thickness excision wounds were created on the dorsal surface of each rat by excising the marked skin area with sterile scissors and forceps. Post-surgery, each rat was housed in a separate cage to prevent cross-contamination and interference with wound sites.

**Ethical approval:** The approval was obtained from the Ahmadu Bello University, Zaria, Committee on Animal Use and Care. The ethical permission number given was ABUCAUC/2016/027.



**Plate 1:** The picture of the flowers of *Croton lobatus* and *Croton lobatus* used in the management of wounds in Nigeria, respectively

The rats were randomly assigned to four groups: Group I consisted of three rats that received topical treatments of *C. lobatus* paste (A), *C. lobatus* aqueous extract (B), saline solution (C), and Cicatrin powder (D) on their respective wounds, with the treatment regimen rotated in a clockwise manner for each rat to ensure that each wound received a different treatment; Group II was similar to Group I, with three rats treated with the four different agents in a rotated manner; Group III also consisted of three rats, with treatments applied as described above; and Group IV, comprising four rats, was designated for histological and biochemical analyses, with one rat sacrificed on days 4, 7, 10, and 13 post-wounding to collect tissue samples for these assessments. In Groups I to III, wound healing progression was monitored through gross examination, focusing on parameters such as wound contraction and epithelialization. These observations were recorded on days 4, 6, 8, 10, and 12 post-wounding. On day 22, following complete healing, biopsies were collected from these groups for tensometric analysis to assess the mechanical strength of the healed tissues. In Group IV, the sequential sacrifices allowed for the collection of granulation tissue samples at different healing stages. These samples underwent histopathological examination and biochemical assays to quantify levels of hydroxyproline, hexosamine, total protein, and uronic acid, providing insights into the biochemical milieu of the healing wounds.

**Wound evaluation:** The wounds were evaluated for signs of infection, including the presence of pus, necrotic tissue development, foul odor, and exudate production. Wound retraction was also systematically measured. To monitor wound contraction, a modified version of the planimetric method [17] was employed. This involved tracing the wound edges onto clean tracing paper on days 2, 4, 6, 8, 10, and 12 post-wounding. These tracings were subsequently analyzed using graph paper to calculate the wound area. The percentage of wound contraction and epithelialization was determined using the following formulas:

**Histopathological testing:** To evaluate the wound healing process, one animal from Group IV was sacrificed on days 4, 7, 10, and 13 post-wounding. The entire wound areas were excised, and samples were collected for histopathological and biochemical analyses. Tissue samples designated for histopathological examination were fixed in 10.0% neutral buffered formalin, dehydrated through ascending grades of ethanol, cleared in xylene, and embedded in molten paraffin wax. Sections of 2-4  $\mu\text{m}$  thickness were prepared and stained with hematoxylin and Eosin (H & E) for general structural assessment, while Masson's Trichrome stain was employed to evaluate collagen deposition. Histological evaluation was conducted using Abramov's histological scoring system [18, 19]. This semi-quantitative system assesses parameters such as acute and chronic inflammation, granulation tissue formation, fibroblast proliferation, collagen deposition, re-epithelialization, and neovascularization, assigning scores from 0 to 3 for each parameter. This allows for a comprehensive assessment of the wound-healing process.

**Tensometry (measure of tensile strength):** On day 22 post-healing, bisected biopsies were obtained from the fully healed wounds. Tensile strength for each sample was measured using a digital force gauge machine (HF-200; model FKP Algometer produced by WAGNER), following established procedures [20].

**Biochemical tests:** Biopsies were collected on day 22 post-wounding from rats in Group IV, following the healing of the last wound. The collected wounds were processed for histopathological and biochemical analyses. Tissue samples were fixed in 10.0% neutral buffered formalin, dehydrated through ascending grades of ethanol, cleared in xylene, and embedded in molten paraffin wax. The resulting blocks were sectioned into 2-4  $\mu$ m slices and stained with (H & E) to assess general tissue structure. For collagen evaluation, Masson's green trichrome stain was employed. Histological assessment utilized Abramov's scoring system [18, 19]. Hydroxyproline and hexosamine contents were quantified using the methods [21, 22], respectively, as referenced [23]. The total protein content in the granulation tissue was determined using Bradford's method [24]. Uronic acid levels were measured according to the procedure [25].

**Statistical analysis:** Data were presented as means $\pm$ standard error of the mean (SEM). Statistical analyses were performed using one-way and two-way analysis of variance (ANOVA) as appropriate, followed by the Bonferroni post hoc test for multiple comparisons, considering time as a factor.  $P < 0.05$  was deemed statistically significant.

## Results

On days 4 and 7 post-wounding, the scabs formed on the wounds were carefully removed for assessment. The ease of scab removal was evaluated by noting the firmness of attachment to the wound bed, with particular attention to any sticky or gel-like substances present. This evaluation was performed according to the method described [17]. Regarding wound exudate, its characteristics volume, color, and odor were assessed as per the guidelines provided by the World Union of Wound Healing Societies [26]. These assessments are crucial for understanding the wound's healing environment and were documented as outlined in the Wound Assessment and Management Guidelines [27]. On day 3 post-wounding, 75.0% of the square-shaped wounds had transformed into irregular circular shapes. Scabs formed from wound exudates on days 4 and 7 were carefully debrided. Scabs on Cicatrin-treated wounds were firmly attached to the wound beds, exhibiting sticky, gel-like materials.

**Table 1:** Assessment of the ease of scab removal (debridement) on days 4 and 7 of wounds treated with *C. lobatus*

Day	A	B	C	D
4	3 $\pm$ (2-3) <sup>a</sup>	3 $\pm$ (3-3) <sup>a</sup>	2 $\pm$ (1-3) <sup>ab</sup>	0 $\pm$ (0-1) <sup>b</sup>
7	3 $\pm$ (2-3) <sup>a</sup>	3 $\pm$ (3-3) <sup>a</sup>	2 $\pm$ (1-2) <sup>b</sup>	0 $\pm$ (0-1) <sup>b</sup>

<sup>abc</sup>Means in the same row with different superscript alphabets were significantly different, A (*C. lobatus* paste); B (*C. lobatus* aqueous extract); C (normal saline); D (Cicatrin powder), 0 (poor); 1 (good); 2 (very good) and 3 (excellent)

**Table 2:** Evaluation of scab (exudate) from the wounds treated with *C. lobatus* on days 4 and 7

Day	A	B	C	D
4	3 $\pm$ (2-3)	2 $\pm$ (2-3)	2 $\pm$ (1-3)	2 $\pm$ (2-3)
7	2 $\pm$ (2-3)	2 $\pm$ (2-2)	2 $\pm$ (2-3)	2 $\pm$ (2-3)

<sup>abc</sup>Means in the same row with different superscripts alphabets were significantly different. A (*C. lobatus* paste); B (*C. lobatus* aqueous extract); C (normal saline); D (Cicatrin powder), 0 (none); 1 (scanty); 2 (moderate) and 3 (abundant)



**Table 3:** Mean of percentage wound contraction on the days 4, 6, 8, 10, and 12 of wound healing using *C. lobatus*

Day	A	B	C	D
4	4.13±3.82 <sup>a</sup>	24.54±6.37 <sup>b</sup>	9.43±8.77 <sup>a</sup>	3.56±5.56 <sup>a</sup>
6	62.42±3.66 <sup>a</sup>	71.48±3.37 <sup>a</sup>	61.96±5.37 <sup>ab</sup>	51.73±4.96 <sup>b</sup>
8	82.84±3.32	88.77±1.58	86.06±1.56	81.96±3.04
10	91.61±1.31	93.89±0.98	90.23±0.96	89.32±1.13
12	92.29±1.21	94.10±0.90	86.50±5.76	90.00±1.16

<sup>abc</sup>Means in the same row with different superscripts alphabets were significantly different  
A (*C. lobatus* paste); B (*C. lobatus* aqueous extract); C (normal saline) and D (Cicatrion powder)

**Table 4:** Mean of percentage wound epithelialisation on the days 8, 10 and 12 of wound healing using *C. lobatus*

Day	A	B	C	D
8	62.10±4.93	59.58±5.62	50.61±9.24	39.55±9.85
10	82.62±6.01 <sup>a</sup>	84.63±5.15 <sup>a</sup>	76.87±5.56 <sup>ab</sup>	55.52±10.99 <sup>b</sup>
12	96.67±3.33	96.44±3.56	87.49±4.41	76.43±6.88

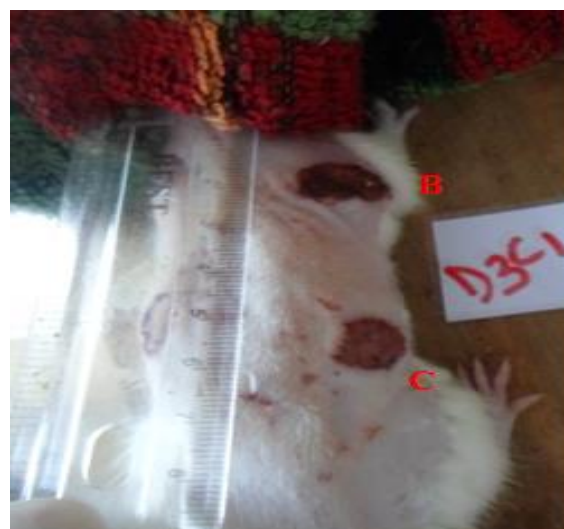
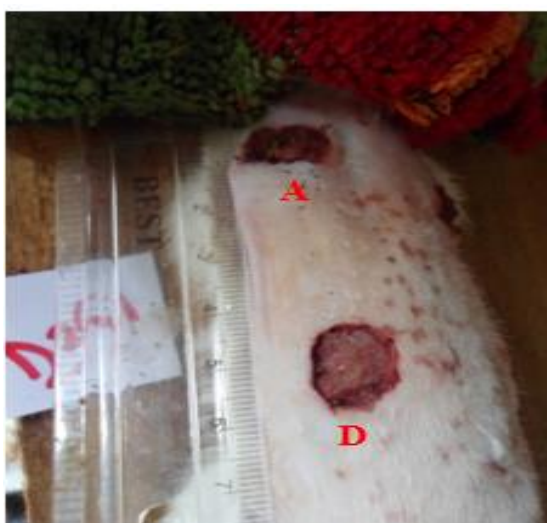
<sup>abc</sup>Means in the same row with different superscripts alphabets were significantly different  
A (*C. lobatus* paste); B (*C. lobatus* aqueous extract); C (normal saline) and D (Cicatrion powder)

The mean values for percentage wound contraction increased with days in all the treated wounds with slight differences. The highest rate of wound contraction occurred in all the treated groups on day 6 (**Table 3**). Epithelialisation started on day 7 and reached its highest rate at day 10 (**Table 4**).

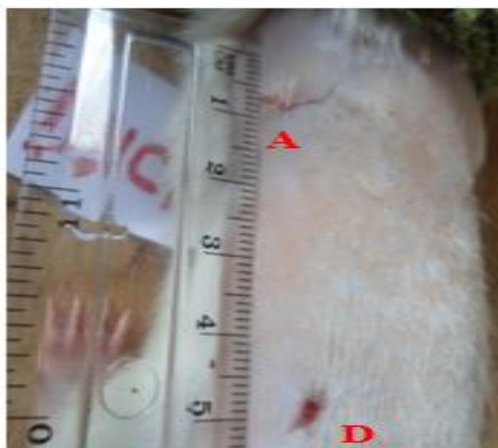
Histological examination of granulation tissues from wounds treated with *C. lobatus* revealed a moderate to abundant presence of fibroblasts compared to the scanty fibroblasts observed in wounds treated with saline solution (**Figure 1**) and Cicatrion (**Figure 2**). Similarly, collagen deposition was moderate to abundant in the *C. lobatus* treated wounds (**Figure 3**) and, *C. lobatus* aqueous extract (**Figure 4**) respectively, whereas fewer polymorphonuclear cells were present. By day 13 post-wounding, epithelialization was complete in the *C. lobatus* treated wounds, exhibiting an abundance of keratinocytes.

The mean tensile strength values measured on day 22 post-wounding were 437.40±8.79 g/cm<sup>2</sup> for wounds treated with *C. lobatus* paste and 163.00±27.75 g/cm<sup>2</sup> for those treated with Cicatrion powder (**Table 5**).

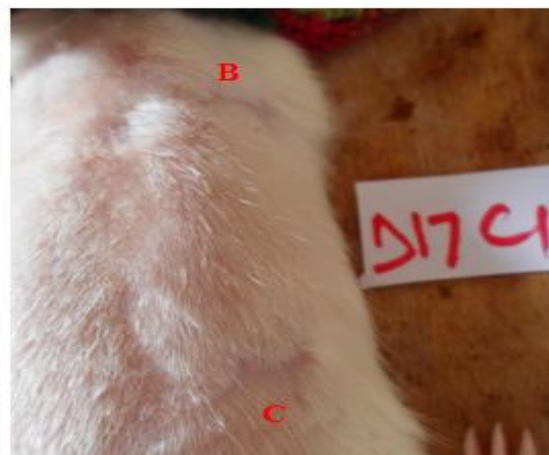
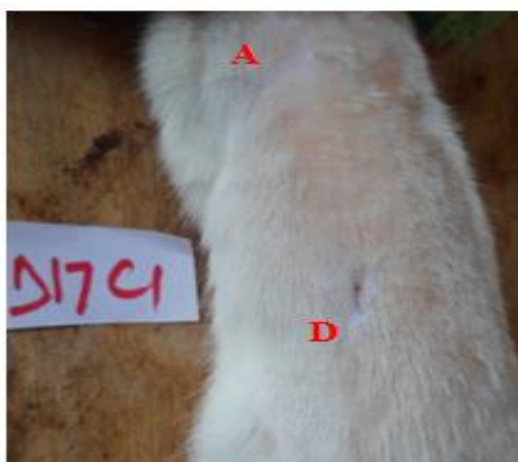Day 3



Day 11



Day 17

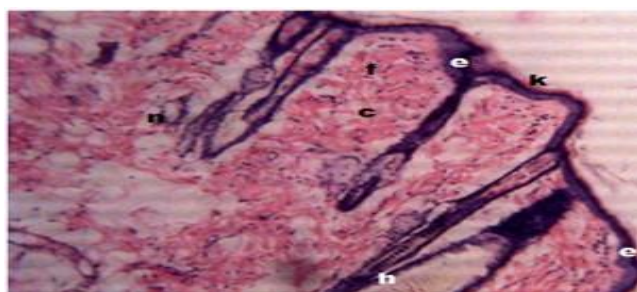


**Plate 2:** Transformation of all the wounds into irregular circular wounds at day 3; complete epithelialisation and healing of wounds treated with *C. lobatus* paste (A) and aqueous extracts (B) on day 11; and normal saline (C) on day 17 (A, *C. lobatus* paste, B, *C. lobatus* aqueous extract, C, normal saline, and D, Cicatrin powder)

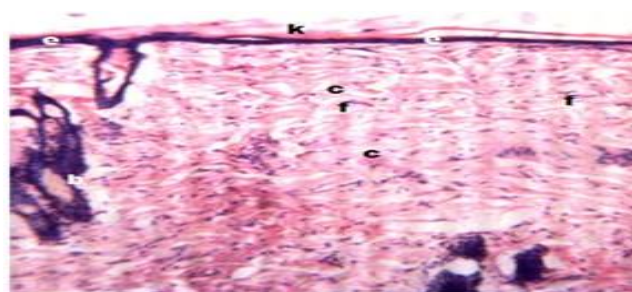
**Table 5:** Mean values of tensile strength of tissues (g/cm<sup>2</sup>) from various healed wounds treated with *C. lobatus* aqueous extract at day 22

Day	A	B	C	D
22	437.4±8.79	384.8±68.5	312.5±3.82	206.5±89.81

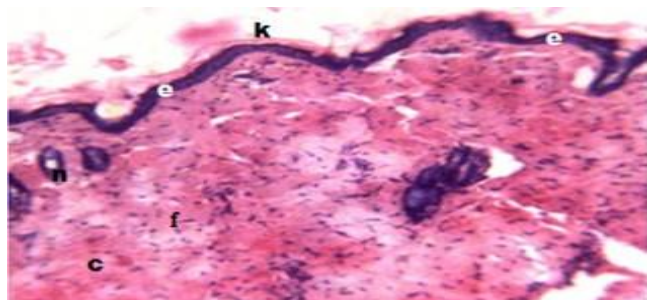
<sup>abc</sup>Means in the same row with different superscript alphabets were significantly different  
A (*C. lobatus* paste); B (*C. lobatus* aqueous extract); C (normal saline) and D (Cicatrin powder)



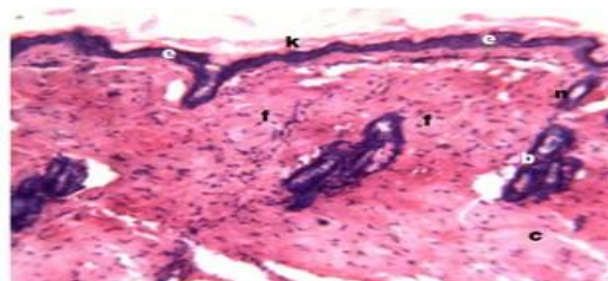
**Figure 1:** Micrograph of the granulation tissue harvested on day 13 post-wounding from the wound treated with normal saline



**Figure 2:** Micrograph of the granulation tissue harvested on day 13 post-wounding from the wound treated with Cicatrin powder



**Figure 3:** Micrograph of the granulation tissue harvested on day 13 post wounding from the wound treated with *C. lobatus* paste



**Figure 4:** Micrograph of the granulation tissue harvested on day 13 post wounding from wound treated with *C. lobatus* aqueous extract,

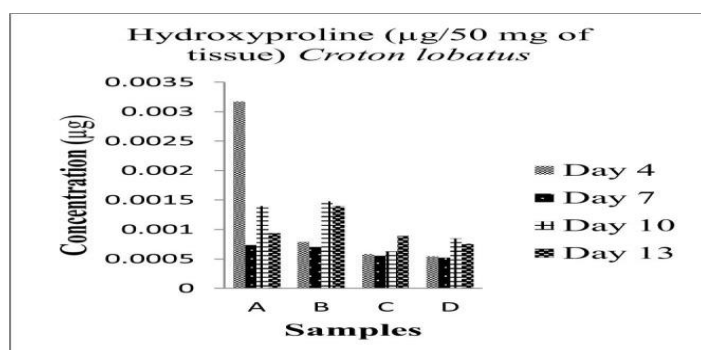
Wounds that were treated with *C. lobatus* paste healed within the shortest period ( $11.0 \pm 0.33$  days), followed by *C. lobatus* aqueous extract at ( $11.22 \pm 0.40$ ). Cicatrin-treated wounds had the longest period of wound healing ( $17.56 \pm 1.04$ ) days (**Table 6**).

**Table 6:** Mean value of time (days) it took for the wounds treated with *C. lobatus* aqueous extract to heal

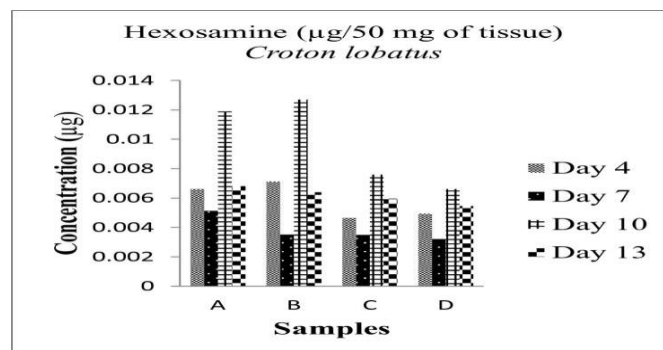
A	B	C	D
$11 \pm 0.33^a$	$11.22 \pm 0.40^a$	$12.33 \pm 0.50^a$	$17.56 \pm 1.39^b$
(10-12)	(10-13)	(10-14)	(10-22)

<sup>abc</sup>Means in the same row with different superscripts alphabets were significantly different A (*C. lobatus* paste); B (*C. lobatus* aqueous extract); C (normal saline) and D (Cicatrin powder).

As illustrated in **Figure 5**, the biochemical composition of granulation tissue from wounds treated with different agents, *C. lobatus* paste (Group A), *C. lobatus* aqueous extract (Group B), normal saline (Group C), and Cicatrin powder (Group D), showed significant variation. On day 4, Group A exhibited the highest hydroxyproline concentration. However, by day 13, Group B showed a greater increase in hydroxyproline than all other groups. Group C and group D consistently recorded the lowest values across all parameters. In **Figure 6**, hexosamine peaked on day 10, with Group B having the highest concentration, followed by Group A, Cicatrin (Group D), and normal saline (Group C). A similar pattern was observed in uronic acid levels (**Figure 7**), where Group B slightly exceeded Group A, with Group C showing the lowest values. Total protein concentration (**Figure 8**) mirrored this trend, with Groups A and B outperforming Groups C and D.

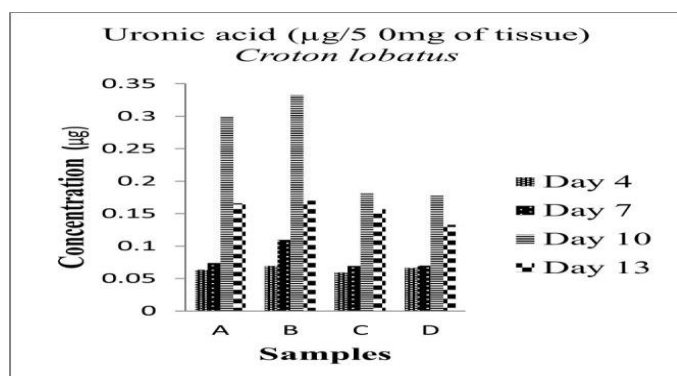


**Figure 5:** Biochemical estimation of hydroxyproline ( $\mu\text{g}$ ) of granulation tissue samples harvested from healing wounds treated with different agents (A, B, C & D)

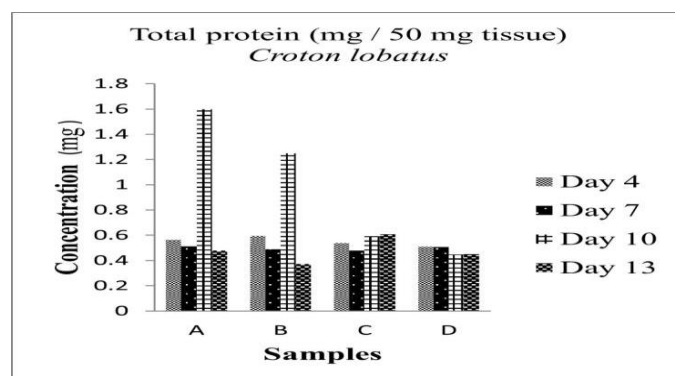


**Figure 6:** Biochemical estimation of hexosamine ( $\mu\text{g}$ ) of granulation tissue samples harvested from healing wounds treated with different agents (A, B, C & D)





**Figure 7:** Biochemical estimation of uronic acid ( $\mu\text{g}$ ) of granulation tissue samples harvested from healing wounds treated with different agents (A, B, C & D)



**Figure 8:** Biochemical estimation of total protein ( $\mu\text{g}$ ) of granulation tissue samples harvested from healing wounds treated with different agents (A, B, C & D)

## Discussion

The study investigated the wound-healing properties of *C. lobatus* paste and aqueous extract, by comparing their effects to those of Cicatrin and normal saline. On days 4 and 7 post-wounding, wounds treated with *C. lobatus* paste and aqueous extract exhibited significantly easier scab removal (debridement) compared to those treated with Cicatrin. This observation is attributed to the gel-like material in Cicatrin-treated wounds, which firmly adhered the necrotic tissue to the wound bed. However, no significant differences were found in the volume of exudates among all treatment groups. This finding contrasts with Sun and others [10], who reported that Dragon's Blood reduced wound exudation compared to their control's animals. At day 4, the mean percentage of wound contraction in *C. lobatus* aqueous extract-treated wounds was significantly higher than in all other groups. By day 6, both *C. lobatus* paste and aqueous extract treatments showed significantly greater contraction compared to Cicatrin, with no significant difference from normal saline. The peak contraction occurred on day 6, aligning with findings by Hinz [28], who also noted that wound contraction typically begins around seven days post-injury due to myofibroblast activity. Similarly, Anietie and associates [30] observed noticeable contraction between days 5 and 9 post-injury [29], while Eugene and others [30] reported a significant decrease in wound area between days 1 and 4 [30] which was different from our findings. Epithelialization commenced around day seven and peaked at day 10. On day 10, wounds treated with *C. lobatus* paste and aqueous extract exhibited significantly higher epithelialization rates than those treated with Cicatrin, with no significant difference from normal saline. This enhanced epithelialization is attributed to the increased mitotic activity of epithelial cells at the wound edges, as supported by the findings by Velnar and associates [31]. The accelerated healing observed with *C. lobatus* treatments is likely due to its saponins, flavonoids, and tannins [32], which possess antioxidant and anti-inflammatory properties that promote granulation tissue formation, fibroblast proliferation, and collagen synthesis. These findings are corroborated by histological and biochemical analysis findings as well.

Histological analysis of granulation tissues from wounds treated with *C. lobatus* demonstrated a notable enhancement in the wound-healing process. Specifically, there was a moderate to abundant presence of fibroblasts in the *C. lobatus* treated wounds, in contrast to the scanty fibroblast population observed in wounds treated with saline solution and Cicatrin. This proliferation of fibroblasts is pivotal, as these cells are integral to synthesizing extracellular matrix components and facilitating tissue repair during the proliferative phase of wound healing [33]. In addition to fibroblast proliferation, collagen deposition was also moderate to abundant in the *C. lobatus* treated wounds [34]. Collagen provides structural integrity to the wound matrix, and its increased deposition indicates a robust healing response. Notably, there were fewer polymorphonuclear cells present in the *C. lobatus*



treated wounds, suggesting a resolution of the inflammatory phase and a transition towards tissue remodeling. By day 13 post-wounding, epithelialization was complete in the *C. lobatus* treated wounds, characterized by an abundance of keratinocytes. The observed histological improvements align with the known roles of fibroblasts in wound healing [33]. Fibroblasts are essential for wound contraction and closure, as they migrate into the wound bed, proliferate, and synthesize new extracellular matrix components, including collagen. Their activity is crucial for the structural restoration of the tissue [35]. The presence of keratinocytes in the healed wounds further indicates successful epithelial regeneration, which is vital for re-establishing the skin's protective barrier. These findings suggest that *C. lobatus* significantly enhances wound healing by promoting fibroblast proliferation [28], collagen deposition, and epithelialization. The observed histological improvements align with the known roles of fibroblasts in synthesizing extracellular matrix components and facilitating tissue repair during the proliferative phase of wound healing. The presence of keratinocytes in the healed wounds further indicates successful epithelial regeneration.

The results of this study demonstrate that wounds treated with *C. lobatus* paste exhibited significantly higher tensile strength on day 22 post-wounding compared to those treated with Cicatrin powder. This finding also suggests that *C. lobatus* paste may enhance wound healing by improving collagen synthesis and tissue remodeling, thereby increasing the tensile strength of the repaired tissue. Biochemical analyses showed that wounds treated with *C. lobatus* paste had the highest hydroxyproline content, indicating increased collagen synthesis. The peak hexosamine content occurred on days 4 and 10 across all treatments, correlating with the highest epithelialization rate and this indicated a more robust collagen synthesis activity, which is critical for tissue repair and wound remodeling. *C. lobatus*-treated wounds also exhibited peak uronic acid content, suggesting enhanced glycosaminoglycan synthesis by fibroblasts. Increased total protein content in these wounds further supported the observed epithelialization rates. These biochemical findings align with the wound-healing effects observed in the histological assessments. The higher hexosamine and uronic acid content in groups A and B further underscores the enhanced extracellular matrix formation, supporting the hypothesis that *C. lobatus*, particularly in paste form, facilitates superior biochemical conditions for granulation tissue formation.

**Conclusion:** *C. lobatus* paste and aqueous extract demonstrated superior wound-healing properties compared to Cicatrin, as evidenced by enhanced contraction, epithelialization, fibroblast activity, collagen deposition, and tensile strength. The plant's bio-active compounds likely contribute to these therapeutic effects, proving its potential as a natural wound-healing agent and hence, these findings collectively suggest that *C. lobatus*-based treatments are more effective than conventional saline and Cicatrin powder in promoting the key biochemical pathways involved in wound healing.

## References

1. Li H, Fu X, Ouyang Y, Cai C, Wang J, Sun T. Adult bone-marrow-derived mesenchymal stem cells contribute to wound healing of skin appendages. *Cell Tissue Research*. 2006; 326(3): 725-736. doi: 10.1007/s00441-006-0270-9
2. Cui HS, Joo SY, Cho YS, Park JH, Kim JB, Seo CH. Effect of combining low temperature plasma, negative pressure wound therapy, and bone marrow mesenchymal stem cells on an acute skin wound healing mouse model. *International Journal of Molecular Sciences*. 2020; 21(10): 3675. doi: 10.3390/ijms21103675
3. Subhashini S, Kantha DA. Investigations on the phytochemical activities and wound healing properties of *Adhatoda vasica* leaves in Swiss albino mice. *African Journal of Plant Sciences*. 2011; 5(2): 133-145. doi: Nil.

4. Wright JB, Lam K, Burrell RE. Wound management in an era of increasing bacterial antibiotic resistance: a role for topical silver treatment. *American Journal of Infection Control*. 1998; 26(6): 572-577. doi: 10.1053/ic.1998.v26.a93527
5. Ogowang PE, Ronald AJ, Joseph O, Evariste B. Wound healing property and phytochemical analysis of *Zanthoxylum* species from Uganda. *Journal of Pharmaceutical Research International*. 2017; 203: 1-9. doi: 10.9734/JPRI/2017/36766
6. Al-Otaibi AM, Al-Gebaly AS, Almeer R, Albasher G, Al-Qahtani WS, Abdel Monei AE. Melatonin pre-treated bone marrow-derived mesenchymal stem cells prompt wound healing in rat models. *Biomedicines and Pharmacotherapy*. 2022; 145: 112473. doi: 10.1016/j.biopha.2021.112473
7. Aldhafer A, Langat M, Schwikkard S, Carew M, Mulholland D. New terpenoids from *Croton dichogamus* Pax. *Planta Medica*. 2016; 81(17): 1512-1517. doi: 10.1055/s-0036-1596327
8. Matara DN, Nguta JM, Musila FM, Mapenay I, Ali HM, Omambia VM. Botanical description, ethnomedicinal uses, phytochemistry and pharmacological effects of *Croton dichogamus* Pax (Euphorbiaceae). *The Journal of Phytopharmacology*. 2021; 10(1): 42-47. doi: 10.31254/phyto.2021.10109
9. Peres ISA, Conceição KAO, Silva LAF, Khouri NG, Yoshida CMP, Concha VOC, et al. Dragon's Blood: Antioxidant properties for nutraceuticals and pharmaceuticals. *Rendiconti Lincei. Scienze Fisiche e Naturali. Scienze Fisiche e Naturali*. 2023; 34: 131-142. doi: 10.1007/s12210-022-01122-4
10. Sun S, Wang P, Yue K, Yi Q, Xie X, Xie X. Effect and mechanism of Dragon's Blood on wound healing of patients with stress hand injury. *Evidence-Based Complementary and Alternative Medicine*. 2023; 2023: 6122331. doi: 10.1155/2023/6122331
11. Guerra Junior JI, Ferreira MRA, de Oliveira AM, Soares LAL. *Croton* sp.: A review about popular uses, biological activities and chemical composition. *Research Society and Development*. 2022; 11(2): e57311225306. doi: 10.33448/rsd-v11i2.25306
12. Burkill HM. *Croton lobatus* L. [family Euphorbiaceae]. In: *The useful plants of west tropical Africa*. Volume 2. Kew: Royal Botanic Gardens; 1985. doi: Nil.
13. Adenuga DA, Ewekeye TS, Sharaibi OJ, Ogundele FO. Inventory of medicinal plants diversity in Atan Okansoso village, APA, Badagry, Lagos State, Nigeria. *Journal of Medicinal Plants Studies*. 2020; 8(4): 176-182. doi: Nil.
14. Odukoya OA, Sofidiya MO, Samuel AT, Ajose I, Onalo M, Shuaib B. Documentation of wound healing plants in Lagos-Nigeria: inhibition of lipid peroxidation as in-vivo prognostic biomarkers of activity. *Annals of Biological Research*. 2012; 34: 1683-1789. doi: Nil.
15. Odewo SA, Ajani BA, Agbeja AO, Oyedeji OF, Soyewo LT, Oyelowo JO, et al. Ethno-botanical survey of indigenous medicinal plants in agroforestry farm of Forest Research Institute of Nigeria, Ibadan, Oyo State, Nigeria. *Journal of Research Forestry Wildlife and Environment*. 2022; 14(3): 10-18. doi: Nil.
16. Prashanthi R, Mohan N, Siva GV. Wound healing property of aqueous extract of seed and outer layer of *Momordica charantia* L. on albino rats. *Indian Journal of Science and Technology*. 2012; 5(1): 1936-1940. doi: 10.1785/ijst/2012/v5i1.18
17. Sharma S, Sharma MC, Kohli DV. Wound healing activity of the ether-chloroform extract of *Momordica charantia* fruits in rats. *Digest Journal of Nanomaterials and Biostructures*. 2010; 5(1): 123-126. doi: Nil.
18. Teoh SL, Latiff AA, Das S. The effect of topical extract of *Momordica charantia* bitter gourd on wound healing in nondiabetic rats and in rats with diabetes induced by streptozotocin. *Clinical and Experimental Dermatology*. 2009; 34(7): 815-822. doi: 10.1111/j.1365-2230.2008.03117.x
19. Piskin A, Zuhail BA, Tümentemü G, Kaplan S, Yazici ÖB, Hökelek M. The beneficial effects of *Momordica charantia* bitter gourd on wound healing of rabbit skin. *The Journal of Dermatological Treatment*. 2014; 25(4): 350-357. doi: 10.3109/09546634.2012.713459
20. Hebda PA, Whaley DL, Kim HG, Wells A. Absence of inhibition of cutaneous wound healing in mice by oral doxycycline. *Wound Repair and Regeneration*. 2003; 11(6): 373-379. doi: 10.1046/j.1524-475x.2003.11510.x
21. Woessner JF. The determination of hydroxyproline in tissue and protein samples containing small proportions of this amino acid. *Archives of Biochemistry and Biophysics*. 1961; 93: 440-447. doi: 10.1016/0003-9861(61)90291-0
22. Randle CJM, Morgan WTJ. The determination of glucosamine and galactosamine. *The Biochemical Journal*. 1955; 61: 586-590. doi: 10.1042/bj0610586
23. Chitra P, Sajithlal GB, Chandrakasan G. Influence of *Aloe vera* on the glycosaminoglycans in the matrix of healing dermal wounds in rats. *Journal of Ethnopharmacology*. 1998; 59(3): 179-186. doi: 10.1016/s0378-8741(97)00112-8

24. Bradford MM. A rapid and sensitive method for the quantitation of microgram quantities of protein utilizing the principle of protein-dye binding. *Analytical Biochemistry*. 1976; 72: 248-54. doi: 10.1016/0003-2697(76)90527-3
25. Chiller S, Slover G, Dorfman AA. A method for the separation of acid mucopolysaccharides: its application to the isolation of heparin from the skin of rats. *The Journal of Biological Chemistry*. 1961; 236: 983-987. PMID: 13747650.
26. World Union of Wound Healing Societies (WUWHS). Wound exudate: Effective assessment and management. London: Wounds International; 2019. Published by Wounds International Ground Floor 108 Cannon Street London EC4N 6EU, UK.
27. Nagle SM, Stevens KA, Wilbraham SC. Worcestershire acute hospitals NHS trust. Wound assessment and management guideline. 2024. Bookshelf ID: NBK482198. PMID: 29489199.
28. Hinz B. Masters and servants of the force: the role of matrix adhesion in myofibroblast force perception and transmission. *European Journal of Cell Biology*. 2006; 85(3-4): 175-181. doi: 10.1016/j.ejcb.2005.09.004
29. Anietie FU, Eze CA, Chah KF, Etuk EU. Antibacterial and surgical wound healing properties of ethanolic leaf extracts of *Swietenia mahagoni* and *Carapa procera*. *Asian Journal of Traditional Medicine*. 2011; 6(6): 272-277. doi: Nil.
30. Eugene I, Igwilo CI, Awodele O, Azubuike C. Antibacterial and wound healing properties of methanolic extract of dried fresh *Gossypium barbadense* leaves. *Asian Journal of Biomedical and Pharmaceutical Sciences*. 2012; 2(13): 32-37. doi: Nil.
31. Velnar T, Bailey T, Smrkolj V. The wound healing process: an overview of the cellular and molecular mechanisms. *Journal of Internal Medicine Research*. 2009; 37: 1528-1542. doi: 10.1177/147323000903700531
32. Subramanian S, Duraipandian C, Alsayari A, Ramachawolran G, Wong LS, Sekar M, et al. Wound healing properties of a new formulated flavonoid-rich fraction from *Dodonaea viscosa* Jacq. leaves extract. *Frontiers in Pharmacology*. 2023; 14: 1096905. doi: 10.3389/fphar.2023.1096905
33. Sakthiganapathi M, Yoganandam GP, Gopal V. Formulation, characterization, and evaluation of wound healing potency of a novel Mattan tailam nanogel based on a famous traditional Siddha formula. *Avicenna Journal of Medicine and Biotechnology*. 2022; 15(1): 38-47. doi: 10.18502/ajmb.v15i1.11423
34. Shadman-Manesh V, Gholipour-Kanani A, Najmoddin N, Rabbani S. Preclinical evaluation of the polycaprolactone-polyethylene glycol electrospun nanofibers containing egg-yolk oil for acceleration of full thickness burns healing. *Scientific Reports*. 2023; 13: 919. doi: 10.1038/s41598-023-28065-6
35. Lambebo MK, Kifle ZD, Gurji TB, Yesuf JS. Evaluation of wound healing activity of methanolic crude extract and solvent fractions of the leaves of *Vernonia auriculifera* Hiern (Asteraceae) in mice. *Journal of Experimental Pharmacology*. 2021; 13: 677-692. doi: 10.2147/JEP.S308303

**Acknowledgments:** We acknowledge the following set of people for all their contributions to this study: Bamidele (Anatomy Department), SB Reuben (Biochemistry Department), Mallam Kabir & Mustapha (Faculty of Pharmaceutical Sciences), and Sanusi (Veterinary Physiology) all from Faculty of Veterinary Medicine, Ahmadu Bello University, Zaria, Kaduna State, Nigeria.

**Author's contributions:** MAK, AZH, and STF initiate the study conceptualization. MAK, LOO, and IOO initiated the study design, methodology, and data analysis. IOO, and AB did the validation and visualization. AB and IOO provided post-study data resources, and MAK, LOO, IOO, AB, HAA, AMO, and AA edited the manuscript. All authors reviewed the manuscript, and approved the final version of the manuscript and agreed to be accountable for its contents.

**Conflict of interest:** The authors declare the absence of any commercial or financial relationships that could be construed as a potential conflict of interest.

**Ethical issues:** The authors completely observed ethical issues including plagiarism, informed consent, data fabrication or falsification, and double publication or submission.

**Data availability statement:** The raw data that support the findings of this article are available from the corresponding author upon reasonable request.

**Author declarations:** The authors confirm that they have followed all relevant ethical guidelines and obtained any necessary IRB and/or ethics committee approvals.